"Snodgraft" Technique for the Treatment of Primary Distal Hypospadias: Pushing the Envelope

Mesrur Selcuk Silay,* Hakan Sirin, Abdulkadir Tepeler, Tuna Karatag, Abdullah Armagan, Kaya Horasanli and Cengiz Miroglu

From the Department of Urology, Bezmialem Vakif University, Faculty of Medicine (MSS, AT, AA) and 2nd Urology Department, Sisli Etfal Training and Research Hospital (HS, TK, KH, CM), Istanbul, Turkey

Abbreviations and Acronyms

DIGU = dorsal inlay graft urethroplasty

M/N-S = meatal and/or neourethral stenosis

TIPU = tubularized incised plate urethroplasty

Submitted for publication February 5, 2012.

Study received Sisli Etfal Training and Research Hospital ethics committee approval and complies with the Helsinki Declaration.

* Correspondence: Bezmialem Vakif Üniversitesi, Tip Fakültesi, Üroloji Anabilim Dali, Adnan Menderes, Bulvari, 34093, Fatih, Istanbul, Turkey (telephone: 90-505-6454005; FAX: 90-212-5332326; e-mail: selcuksilay@gmail.com).

Purpose: "Snodgraft" modification has been proposed to reduce the risk of meatal/neourethral stenosis in distal hypospadias. We applied the Snodgraft technique by using inner preputial graft in primary distal hypospadias repair.

Materials and Methods: A total of 102 consecutive patients undergoing the Snodgraft procedure were prospectively studied between 2006 and 2011. Mean patient age was 7.2 years. Localization of the meatus was glanular in 5 patients, coronal in 49, subcoronal in 45 and mid penile in 3. In all patients the posterior urethral plate was incised, and the graft harvested from the inner prepuce was sutured from the old meatus to the tip of the glans. A neourethra was created over a urethral catheter using 6-zero polyglactin suture. An interpositional flap was laid over the urethra as a second barrier. All patients were followed at 3 to 6-month intervals for cosmetic and functional results.

Results: At a mean of 2.4 years of followup no patient had meatal stenosis or diverticulum at the inlay graft site. However, urethrocutaneous fistula was observed in 10 patients (9.8%). A slit-like appearance of neomeatus was achieved in all patients. During followup no obstructive urinary flow pattern was detected, and early and long-term maximum urine flow rates were comparable.

Conclusions: No meatal/neourethral stenosis was observed in any patient undergoing a Snodgraft procedure. A randomized trial will be needed to prove that the incidence of meatal/neourethral stenosis is lower after Snodgraft repair compared to routine tubularized incised plate repair.

Key Words: hypospadias, transplants, ureter, urologic surgical procedures

TUBULARIZED incised plate urethroplasty has become the most popular technique for repairing distal hypospadias at many institutions during the last 2 decades. Although this technique is easily applicable with good cosmetic results, several complications, including meatal and/or neourethral stenosis, have been reported.[1] Dorsal inlay graft urethroplasty ("Snodgraft") using an inner preputial free graft has been described as an effective method for hypospadias repair with the main advantage of reducing the risk of meatal/neourethral stenosis.[2] Since this modification was first reported in 2000, only a few studies of the modification have been conducted to date.[2–6] Therefore, there is still a lack of evidence to prove the efficacy and safety of this technique.

In the majority of the published series on DIGU the major indications for grafting were the presence of a narrow or shallow glans, or insufficient urethral plate width. At our institution

0022-5347/12/1883-0938/0
THE JOURNAL OF UROLOGY®
http://dx.doi.org/10.1016/j.juro.2012.04.126
Vol. 188, 938-942, September 2012
Printed in U.S.A.

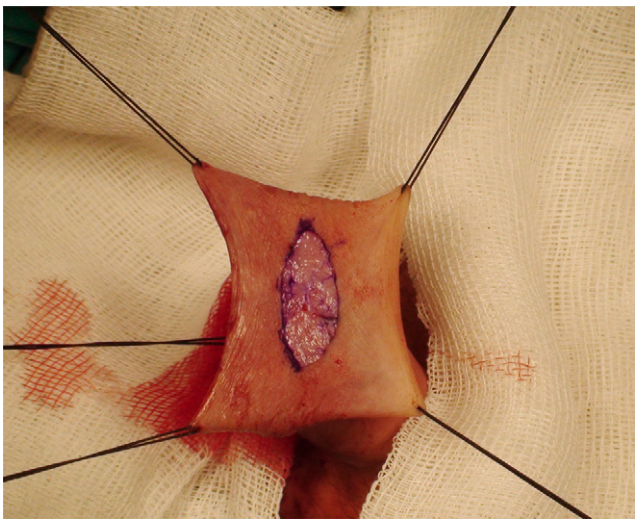

Figure 1. Harvesting of inner prepuce in preparation for DIGU

regardless of the urethral plate characteristics, DIGU has been used since 2006 in every case of distal hypospadias. We report a large series of Snodgraft procedures in the treatment of primary distal hypospadias repair.

MATERIALS AND METHODS

A total of 102 children diagnosed with primary distal hypospadias were prospectively enrolled. Patients with proximal hypospadias, severe chordee, micropenis and circumcised penis were excluded. Distal hypospadias was defined as meatal location distal to the mid penile shaft. The presence of chordee was checked with an artificial erection intraoperatively after degloving the penis when necessary. Micropenis was defined as stretched penile length less than 2.5 SD below mean normal for age. Patients who were previously circumcised for traditional or religious reasons had undergone TIPU alone without grafting and were excluded from the study. The remaining patients with primary distal hypospadias underwent the Snodgraft procedure between October 2006 and February 2011. No patient was lost to followup.

All operations were performed by 2 consultant pediatric urologists (MSS, KH). The surgical procedure was performed according to the description of Kolon and Gonzales.[2] Optical magnification was used for all procedures. After circumferential incision and degloving of the penis, diluted adrenaline solution was injected into the glans to prevent bleeding. A bilateral incision was made along the urethral plate to prepare the wings of the glans. The urethral plate was incised longitudinally in the midline as described by Snodgrass and Nguyen.[1] A small free graft was harvested from the inner preputial skin from the dorsal headpiece, and excess fatty tissue was removed (fig. 1).

The technical principle in harvesting a graft was to prepare adequate tissue to cover the entire incised area of the urethra. Therefore, the length and the width of the graft were subject to change in every case according to the meatal location, urethral plate characteristics and depth of the midline incision. Subsequently the graft was sutured overlying the incision line with 6-zero polyglactin (fig. 2).

The neourethra was rolled around a 6Fr, 8Fr, 10Fr or 12Fr feeding tube or silicon catheter according to patient age and penile size. A double layer running subepithelial 6-zero polyglactin suture was used for urethral closure. An interpositional flap prepared from the dorsal dartos fascia was always laid over the midline as a second barrier for waterproofing. A dartos flap was considered to be a formal vascularized flap mobilized from the dorsum and laid over the neourethra either with the buttonhole maneuver or from the lateral aspect of the penis. The glans wings were then reapproximated with no tension. A 5-zero polyglactin suture was used with the 1-layer mattress suturing technique, and the skin was closed with 4-zero rapid polyglactin after circumcision. Finally, the patient was left with an indwelling catheter and a compressed hypospadias dressing.

Third-generation cephalosporins were applied prophylactically on the day of surgery. The urethral catheters were removed at 24 to 48 hours postoperatively in all cases. All patients were routinely evaluated postoperatively every 3 to 6 months for up to 4 years for cosmetic and functional results. Urethrocutaneous fistula was defined as fistula of the neourethra requiring surgical intervention. M/N-S was defined as symptomatic stenosis re-

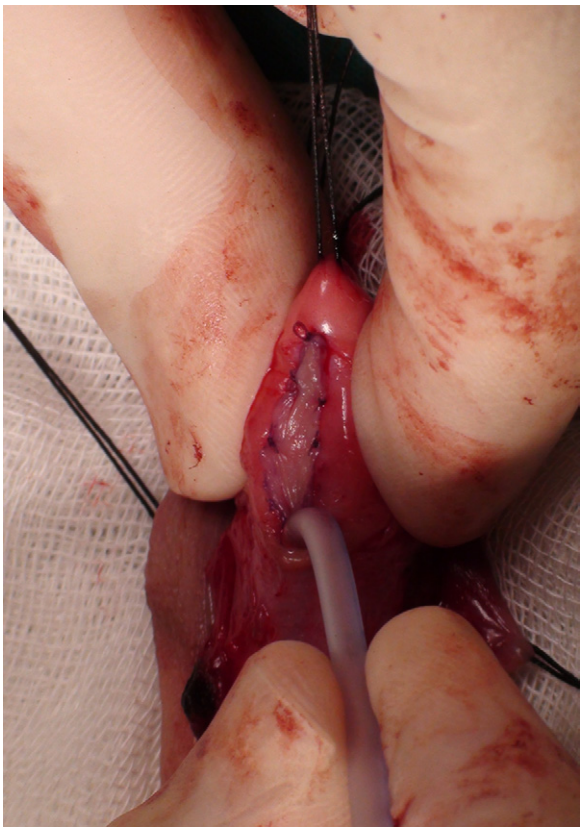

Figure 2. Midline incision of urethral plate is covered with DIGU

quiring dilation or surgical intervention. During followup the external genitalia was routinely examined, voiding symptoms were evaluated and the presence of M/N-S was assessed by checking the calibration of the neourethra with approximately 1 cm insertion of a feeding tube that was the same size as the intraoperative catheter. Additional uroflowmeter studies were performed if possible.

In 41 toilet trained patients urine flow measurements were performed twice, at 1 week and 6 months after the procedure. Children went to the toilet when they had a normal desire to void. The uroflowmeter was set in the toilet to create a familiar environment. Boys were asked to void in the standing position. Voided volume more than 50% of expected bladder capacity was considered satisfactory uroflow. The test was repeated when the voided volume was insufficient or when the result was inconsistent with the physical examination and history. The presence of a plateau pattern was considered a sign of obstruction. Early and long-term uroflowmetric parameters were statistically compared. Overall acceptable cosmetic appearance of the penis was decided according to the slit-like appearance of the neomeatus, the straight position of the penis and the satisfaction of the surgeon and parents.

Values were provided as mean ± SD. Wilcoxon test was used for analyses and $p < 0.05$ indicated statistical significance. This study was approved by the ethics committee of Sisli Etfal Training and Research Hospital, and complies with the Helsinki Declaration.

RESULTS

Mean ± SD patient age at surgery was 7.26 ± 4.24 years (range 1 to 17). Localization of the hypospadic urethral meatus was glanular in 5 patients, coronal in 49, subcoronal in 45 and mid penile in 3. The urethral catheter was removed at a mean ± SD of 1.67 ± 0.78 days. All patients were discharged home after removal of the urethral catheter and following the observation of voiding.

During a mean ± SD followup of 29.56 ± 12.30 months no patient had a stricture or diverticulum at the inlay graft site. However, urethrocutaneous fistula was detected in 10 children (9.8%) during the first visit. Six months later none of these cases had spontaneously healed, and fistula repair was elected and successfully performed in all. M/N-S was not found in any of these patients as evidenced by checking the calibration of the neourethra during fistula repair. Other complications, such as severe bleeding or hematoma, wound infection or dehiscence of the glans or preputial wings, were not observed in any patient. A straight penis without dorsal plication of the corpora cavernosa and a slit-like appearance of the neomeatus with an acceptable cosmetic appearance of the penis was achieved in all cases. Overall success rate was 90.2%.

A total of 58 boys were toilet trained at operation. No child presented with voiding symptoms or urinary stream abnormalities. Uroflowmetry was performed in children only if they were toilet trained, were able to void volitionally and had no urethrocutaneous fistula following hypospadias repair. Urine flow measurements were available in 41 patients and were performed twice, at 1 week and 6 months postoperatively. The results did not demonstrate any sign of obstruction, and a normal bell-shaped urinary flow pattern was achieved in all children. No significant difference was detected between early and long-term maximum urine flow rates (mean ± SD 8.46 ± 3.47 vs 9.43 ± 5.14 ml per second, $p = 0.109$).

DISCUSSION

In patients with primary distal hypospadias the Snodgraft procedure using an inner preputial free graft prevents M/N-S. Our results show that this technique is applicable not only in the presence of a narrow or shallow glans, but also for distal hypospadias operations.

M/N-S is the second most common complication following hypospadias repair.[7] Gonzalez and Ludwikowski previously highlighted the importance of this worrisome complication and predicted that urologists will need to treat a number of patients with this problem in the next 2 decades.[8] The incidence has been reported at 4.7% (range 0% to 19%) in the literature.[4] The condition can either be treated with urethrotomy, with dilation or conservatively but it is often unrecognized and thus underdiagnosed.

Some authors have suggested the regular use of neourethral bouginage postoperatively to prevent M/N-S.[9] Others have tried to create modifications to overcome the situation. Kolon and Gonzales introduced the Snodgraft technique, which uses the inner prepuce, in 2000.[2] They applied this modification in 32 patients successfully without the development of M/N-S after 21 months of followup. The main idea of this modification is that leaving the neourethra with a large denuded surface likely to reepithelialize and scar would be the leading factor for M/N-S. With the insertion of a free inlay graft they aimed to preserve the urethral plate and increase the area of the healthy tissue. They concluded that Snodgraft fulfilled the traditional hypospadias repair criteria and was a successful addition to the armamentarium of the hypospadiologist. However, since the publication of that report only a few studies have been conducted using this modification in primary cases (see table).

Ferro et al reported selection criteria to apply the Snodgraft procedure for primary distal hypospadias cases.[6] They found that when patients have an anatomically abnormal glans with a diameter of less than 2.5 SD for age, a flat urethral groove producing a round glans and/or a long spongiosum defect, they

Current series of DIGU (Snodgraft) using inner preputial graft for primary hypospadias repair

References	No. Pts	No. Urethrocutaneous Fistulas (%)	No. Glans Dehiscence (%)	Catheterization (days)
Kolon and Gonzales[2]	32	—	2 (6.2)	Not reported
Gundeti et al[3]	14	1 (7.1)	—	7
Asanuma et al[4]	28	1 (3.6)	—	10–14
Singh and Pavithran[5]	25	4 (16.0)	—	15
Ferro et al[6]	18	—	—	7–10
Present series	102	10 (9.8)	—	1–2

No patient had meatal/neourethral stenosis.

are suitable for the Snodgraft procedure. Gundeti et al also support the idea of the application of this technique in patients who lack a urethral groove or have a small glans.[3] None of the 14 children in their study exhibited M/N-S at 18 months of followup. Another study of 28 primary hypospadias cases revealed similar complication rates regarding M/N-S.[4] A more recent study comparing the Snodgraft and Snodgrass techniques in primary and multistaged cases demonstrated a significant superiority of Snodgraft.[10] In this retrospective study after a mean followup of 3.6 years the authors found that M/N-S had developed in only 1 of 50 patients with the Snodgraft repair, compared to 8 of 50 with the Snodgrass repair. Although the nonrandomized design could be a limitation of the study, the application of Snodgraft in select cases was strongly advocated.

In our study we used the Snodgraft modification in 102 consecutive primary cases and extended the application of this procedure. None of our patients exhibited M/N-S, and the overall success rate was 90.2%. A straight penis without dorsal plication of the corpora cavernosa and a slit-like appearance of the neomeatus with an acceptable cosmetic appearance of the penis was achieved in all cases. The prospective evaluation of the uroflowmetric parameters also supported the clinical followup results regarding M/N-S. We have shown that this modification can be applied not only in cases of narrow or shallow glans, but also in distally located hypospadias.

Another technical factor that might lead to meatal stenosis is tubularization of the urethral plate too far distally.[11] This is theoretically possible, especially in inexperienced hands. On the other hand some other investigators have proposed that urethral plate characteristics are the most important factor in the development of M/N-S.[12] This is also our clinical impression in our patients and according to similar series investigating the development of M/N-S (see table).

The only disadvantage of this technique is the time spent preparing the inner preputial free graft. An additional 15 to 20 minutes is required according to the published series.[2–6] We found that a mean of 18 minutes was spent in insertion of the graft in our patients. However, considering the risk of meatal/neourethral stricture and the additional treatments that might be necessary, a 20-minute delay before operating should not be considered a significant limitation of this technique.

One limitation of our study might be the catheterization period after hypospadias repair. It could be argued that the shorter catheterization time in our patients might lead to increased overall complication rates, particularly urethrocutaneous fistula. However, based on the published series of Snodgraft repair, there is no standard timing for the removal of the urethral catheters, and the catheterization periods vary from 4 to 15 days.[3–6,10] Additionally, even stent-free surgery has been a choice of treatment in distal hypospadias cases, and the success and complication rates after Snodgrass repair are satisfactory.[13,14] Therefore, it is a preference of our department to leave the catheter for 24 to 48 hours and to discharge the patient home just after observing voiding. Going home without a stent provides additional comfort to the children and their parents. The comparable complication rates in our patients support the safety of our preferred approach.

Another limitation of our study is the lack of a control group. Although none of our patients exhibited M/N-S during followup out to 4 years, in accordance with other series (see table) it is impossible to suggest the superiority of this technique over Snodgrass repair unless randomized controlled trials have been conducted. However, hypospadiologists should devote more attention to preventing this potentially worrisome complication, which is probably underestimated.

CONCLUSIONS

To our knowledge this is the largest series of Snodgraft procedure using inner preputial graft in primary distal hypospadias repair. The technique was successfully performed in distal hypospadias. No meatal/neourethral stenosis developed in any patient. A randomized trial will be needed to prove that the incidence of meatal/neourethral stenosis is lower after a Snodgraft procedure compared to routine TIPU.

REFERENCES

1. Snodgrass WT and Nguyen MT: Current technique of tubularized incised plate hypospadias repair. Urology 2002; **60:** 157.
2. Kolon TF and Gonzales ET: The dorsal inlay graft for hypospadias repair. J Urol 2000; **163:** 1941.
3. Gundeti M, Queteishat A, Desai D et al: Use of an inner preputial free graft to extend the indications of Snodgrass hypospadias repair (Snodgraft). J Pediatr Urol 2005; **1:** 395.
4. Asanuma H, Satoh H and Shishido S: Dorsal inlay graft urethroplasty for primary hypospadiac repair. Int J Urol 2007; **14:** 43.
5. Singh RB and Pavithran NM: Lessons learnt from Snodgrass tip urethroplasty: a study of 75 cases. Pediatr Surg Int 2004; **20:** 204.
6. Ferro F, Vallasciani S, Borsellino A et al: Snodgrass urethroplasty: grafting the incised plate—10 years later. J Urol 2009; **182:** 1730.
7. Wilkinson DJ, Farrelly P and Kenny SE: Outcomes in distal hypospadias: a systematic review of the Mathieu and tubularized incised plate repairs. J Pediatr Urol 2012; **8:** 307.
8. Gonzalez R and Ludwikowski BM: Importance of urinary flow studies after hypospadias repair: a systematic review. Int J Urol 2011; **18:** 757.
9. El-Bakry A: Tubularized-incised plate urethroplasty: is regular dilatation necessary for success? BJU Int 1999; **84:** 683.
10. Shimitokahara A, Nakazawa N, Wada A et al: Tubularized incised plate urethroplasty with dorsal inlay graft prevents meatal/neourethral stenosis: a single surgeon's experience. J Pediatr Surg 2011; **46:** 2370.
11. Nguyen MT and Snodgrass WT: Effect of urethral plate characteristics on tubularized incised plate urethroplasty. J Urol 2004; **171:** 1260.
12. Holland AJ and Smith GH: Effect of depth and width of the urethral plate on tubularized incised plate urethroplasty. J Urol 2000; **164:** 489.
13. Turial S, Enders J, Engel V et al: Stent-free tubularized incised plate (TIP) repair of distal and mid-shaft hypospadias irrespective of age. Eur J Pediatr Surg 2011; **21:** 168.
14. Leclari MD, Camby C, Battisti S et al: Unstented tubularized incised plate urethroplasty combined with foreskin reconstruction for distal hypospadias. Eur Urol 2004; **46:** 526.

EDITORIAL COMMENT

The authors do not cite our outcomes in 426 consecutive patients undergoing distal hypospadias repair.[1] All underwent TIPU—there was no selection bias regarding urethral plate width or depth, or size or shape of the glans, which is important since these are subjective descriptions that surgeons examining the same patients likely would characterize differently. No patient had symptoms of urinary obstruction, and 65% underwent calibration, uroflowmetry and/or urethroscopy that did not reveal stenosis. The 1 boy diagnosed with meatal stenosis presented with balanitis xerotica obliterans 6 years after repair.

When TIPU was introduced, there was concern the dorsal incision would stenose. Our data, an average meatal stenosis rate of 5% or less, and only anecdotal strictures in other published reports indicate the incision reepithelializes without stenosis. Consequently meatal stenosis results from technical error (inadequate incision depth, plate tubularization too far distally) rather than unfavorable plate or healing characteristics. Despite these data, some surgeons still worry about dorsal incision healing. This report indicates grafting can be done without increasing complications.

Warren Snodgrass
Children's Medical Center
UT Southwestern Medical Center
Dallas, Texas

REFERENCE

1. Snodgrass W, Bush N and Cost N: Tubularized incised plate hypospadias repair for distal hypospadias. J Pediatr Urol 2010; **6:** 408.