Accepted Manuscript

Micro-Ureteroscopy for the Treatment of Distal Ureteral Calculi in Children

Mehmet Mazhar Utanğaç, Ahmet Ali Sancaktutar, Abdulkadir Tepeler

PII: S0022-3468(16)30579-6
DOI: doi: 10.1016/j.jpedsurg.2016.11.032
Reference: YJPSU 57928

To appear in: *Journal of Pediatric Surgery*

Received date: 23 June 2016
Revised date: 25 August 2016
Accepted date: 4 November 2016

Please cite this article as: Utanğaç Mehmet Mazhar, Sancaktutar Ahmet Ali, Tepeler Abdulkadir, Micro-Ureteroscopy for the Treatment of Distal Ureteral Calculi in Children, *Journal of Pediatric Surgery* (2016), doi: 10.1016/j.jpedsurg.2016.11.032

MICRO-URETEROSCOPY FOR THE TREATMENT OF DISTAL URETERAL CALCULI IN CHILDREN

Mehmet Mazhar Utanğaç[1], Ahmet Ali Sancaktutar[1], Abdulkadir Tepeler[2]

[1]Department of Urology, Faculty of Medicine, Dicle University, Diyarbakir, Turkey
[2]Department of Urology, Faculty of Medicine, Bezmialem Vakif University, Istanbul, Turkey

Key words: Children, distal ureteral calculi, ureteroscopy, miniaturization, efficacy, and safety

Corresponding Author:
Mehmet Mazhar UTANĞAÇ, MD
Dicle University, Faculty of Medicine, Department of Urology
Diyarbakir, Turkey
Phone: +90 533 8162388
E-mail: drmazhar21@hotmail.com

ABSTRACT

Objective: The objective of this study was to demonstrate the efficacy and safety of micro-ureteroscopy (micro-URS) in the management of distal ureteral stones in the pediatric population.

Materials and Methods: A total of 11 children, who had undergone micro-URS between September 2015 and April 2016 with the indication of distal ureteral calculi in two referral centers, were retrospectively evaluated. The procedures were performed with the patient in the lithotomy position under general anesthesia using the standard URS technique with a micro-ureteroscope that has a caliber of 4.85Fr all along its length. Demographics, perioperative data, and outcomes were assessed.

Results: Right (n=6) and left (n=8) ureteral stones were detected in the respective number of patients. The mean age of the children was calculated as 55.1 months (range, 6-161 months). The median stone size was 10.5 mm (range, 6-24 mm). The median operative time was 36.8 minutes (range, 23-68 mins). A double 3 stent was implanted in 3 of 11 patients due to severe edema. As a postoperative complication mild hematuria (Clavien grade 1) was observed in one case and resolved spontaneously. Intraoperative minor or major complication did not occur in any of the cases. The mean hospitalization time was determined as 21.4 hours (range, 10-28 hours). Stone-free status was accomplished in all patients in the final assessment.

Conclusion: The outcomes of our series show that micro-URS can be used safely and effectively in the treatment of pediatric distal ureteral stones. Further prospective and comparative studies comparing instruments of different size are warranted.

Keywords: children; distal ureteral calculi; ureteroscopy; miniaturization; efficacy; safety

INTRODUCTION

Urolithiasis during childhood differs from stone disease observed in adults in terms of etiology, incidence, and natural course [1]. Because of the higher risk of recurrence and fragile anatomical structure in the treatment of pediatric nephrolithiasis, minimally invasive interventions are strongly preferred. Both in children and adults, shock wave lithotripsy (SWL) and ureteroscopy (URS) are the treatment alternatives based on the stone burden and location [2]. Requirement of multiple sessions for complete stone clearance and its application under anesthesia are the main limitations of SWL in children.

In recent years, technologic innovations, such as miniaturization of endoscopic instruments, have allowed safe and more effective application of minimally invasive methods [3]. It has been reported that when ureteroscopes designed for adults are used in the pediatric age group, complications, such as ureteral injury, ischemia, stenosis, and vesicoureteral reflux, may develop more frequently [4]. Various studies have demonstrated that the use of special smaller caliber ureteroscopes in the treatment of ureteral stones in children decreases complication rates [4,5]. Therefore, in pediatric cases, the use of semirigid ureteroscopes, especially those with a small caliber, is recommended [4,6].

Based on the literature, the smallest caliber (4.8 Fr) endoscope that has been used in the management of renal stones via the percutaneous route has also been employed in the treatment of bladder and distal ureteral stones [7,8]. This method used in the management of cases with ureteral calculi has been denoted “micro-URS” [8,9].

In the present study, we aimed to demonstrate the efficacy and safety of micro-URS in the management of distal ureteral stones in the pediatric population. To our best of knowledge this is the first pediatric series of micro-URS reported in the literature.

MATERIAL AND METHODS

After obtaining the approval of the institutional review board, a total 11 children, who had undergone micro-URS between September 2015 and April 2016 with the indication of distal ureteral calculi in two referral centers, were retrospectively evaluated. The data, including patient demographics, perioperative data and postoperative data, were collected prospectively. Preoperatively, the parents and/or children were informed about potential risks of the procedure, and signed informed consent forms were obtained.

Preoperatively, a routine physical examination and biochemical assessments were performed. Urinary tract infection was investigated with urine cultures in all cases. Plain urinary system radiogram (KUB), ultrasonography, and/or low dose computed tomography was used as the imaging method. Stone burden was expressed as the measurement of the longest diameter of the stone and for multiple stones, as the sum of all of the diameters of the stones.

Micro-ureteroscopy instruments and technique

Micro-ureteroscope is an instrument, including a shaft with 4.85 Fr size and 1.4 mm lumen (Figure 1A), an adaptor attached to the proximal side of the shaft and an optic with the size of 0.9 mm providing image quality of 10.000 pixels (PolyDiagnost, Pfaffenhofen, Germany) (Figure 1). The optic is inserted into the lumen of the shaft through the second lumen of the adapter with 3 lumens. The other lumens allow the insertion of the laser fiber (200µm) and drainage of the irrigation fluid. During the procedure, irrigation was provided using a Y-TUR irrigation set with a pump handle**.**

With the patient in the lithotomy position under general anesthesia, the procedure was performed by the two experienced surgeons (MMU and AT) using the same standard URS technique with a telescope developed for micro-percutaneous nephrolithotomy [8]. During the procedure, a C-arm fluoroscopy device was set ready for use when necessary. **Passage of the optic through the urethra to the bladder and ureteral orifice was easily performed in boys and girls** (Figure 2). Balloon dilation was not needed in any case for access through the ureteral orifice. A guide-wire was used to facilitate the passage in patients with a tortuous ureter. During the procedure, the manual irrigation pump system was used in cases with blurred vision to obtain adequate image quality. Stone fragmentation was accomplished with a 200µm Ho:YAG laser fiber using the dusting technique with the setting of 6Hz and a power of 0.6 joules. In patients who need insertion of a double-J (DJ) stent because of severe edema due to stone impaction or ureteral injury, a guide-wire was inserted through the shaft up to the upper urinary tract. Then, a 4.8 Fr DJ stent was inserted over this guide-wire. **Pain relief was maintained with parenteral or oral analgesics postoperatively (paracetamol 15mg/kg per dose).**

All of the patients were evaluated on the morning of the first postoperative day and one month later using imaging modalities of KUB and US. The patients were discharged on oral analgesia in consideration of the postoperative clinical manifestations. **Two weeks after surgery, DJ stents were removed endoscopically.** Postoperative complications were graded using Clavien-Dindo classification system.

RESULTS

Patient demographics and perioperative data and outcomes are described in Table-1. Right (n=6) and left (n=5) ureteral stones were detected in the respective number of patients. The mean age of the children were calculated as 55.1 months (range: 6-161). **The flank pain (5/11), hematuria (5/11), and fever (4/11) related to urinary tract infection were the main presenting symptoms**. The median stone size was 10.5 mm (range: 6-24). **Upper tract dilation and hydronephrosis was detected in all cases. A double J stent was implanted in 3 of 11 patients due to severe edema intraoperatively.** The median operative time was 36.8 minutes (range: 23-68). As a postoperative complication mild hematuria (Clavien grade 1) was observed in one case and resolved spontaneously. Intraoperative minor or major complication was not occurred in any of the cases. The mean hospitalization time was determined as 21.4 hours (range: 10-28). Stone free status was accomplished in all patients in the final assessment. **In the first month control visit, residual fragments, hydronephrosis or any sign of urinary tract infection was not detected.**

DISCUSSION

Although pediatric stone disease is rare, its overall incidence is nearly 2-3 percent [10]. In children, ureteral stones are seen less frequently compared to adults, and they constitute nearly 7% of all urinary stones [11]. During the last two decades, minimally invasive interventions, such as SWL, URS, percutaneous nephrolithotomy, and laparoscopic surgery, which have been applied initially in adults, have been modified for use in pediatric patients [10].

The first use of URS for distal ureteral calculi in children was reported by Ritchey in 1988 [12]. With the miniaturization of ureteroscopes and the development of laser lithotripsy, URS use in the pediatric age group has become increasingly prevalent [Table 2]. The effective and safe use of URS in the pediatric age group has been emphasized in a recently published review [10]. Despite the effectiveness, ureteroscopy carries the risks of complications [13]. Development of complications is apparently related to the use of optical instruments of very large calibers. In the literature, ureteroscopes with caliber sizes ranging from 4.5 to 8 Fr have been used in pediatric population [14,15]. In a study it was emphasized that despite the effectiveness of URS in the pediatric age group, extra measures should be

taken in patients younger than 5 years of age due to increased risk of complications [4]. Our series included 10 pre-school children and 1 adolescent. The mean age of the patients was calculated as 55.1 months.

In a study comparing 4.5 Fr and 7.5 Fr ureteroscopes in the management of ureteral stones in 69 preschool children, the 4.5 Fr ureteroscope was revealed to be an ideal optic in the pediatric age group [5]. In this study, the success rate was significantly higher in the smaller size URS group (92.6 % vs. 78.6%). In a study performed in 36 prepubertal children, the authors stressed that small caliber ureteroscopes can be used safely and effectively in children without the need for active or passive dilatation [16]. In their series authors achieved stone free status in 97.4% of the cases.

The micro-optic shaft, which was designed to fragment renal stones in the collecting system via the percutaneous route, has been used for various purposes [17,18]. This micro-optic, which has a caliber of 4.85 Fr all along its length, has been used in the management of distal ureteral stones in adult women [8]. Recently authors reported the first pediatric case with distal ureteral calculi treated with micro-URS [9]. Despite the use of ureteroscopes with tips of different caliber sizes in the literature, the caliber of the optics gradually increases towards the proximal part (Figure 1B). For example, the proximal 5 cm of the ureteroscope with the smallest caliber known to date has a diameter of 4.5 Fr, while the remainder of the instrument is thicker (6,5 Fr). In the current study we present our series and demonstrate the effectiveness of micro-URS in the management of distal ureteral stones in pediatric patients. **Based on our literature review, our patient series is the first pediatric series having undergone micro-URS for the management of ureteral stones.**

Some advantages of the optic used during micro-URS have been mentioned in previous reports. Especially, due to its smaller size, it can easily pass through the urethra and ureter. It allows good quality images similar to those of standard URS, and it enables the passage of fragmented stones during the procedure. Because its optical shaft is shorter, thinner, flexible, and less traumatic than the other conventional ureteroscopes, we think that it is more appropriate for children. Because of the small irrigation lumen and passage of the fluid around the sheath during procedure, increase of the pressure in the collecting system is prevented. Thereby the risk of bacteremia related to high pressure is reduced. Moreover, migration of stone fragments into the upper collecting system is prevented.

Although as a procedure pediatric ureteroscopy resembles adult ureteroscopy, ureteral access can be especially challenging. **In the literature, the need for dilation of the ureteral orifice is reported to range between 0 and 100% depending on the size of the**

ureteroscope used during procedure [Table-2][14]. Forced mechanical dilation of the distal ureter may lead to ischemic damage and recurrent stenosis [5]. **A long-term potential risk of ureteral orifice dilation is vesico-ureteral reflux. In a study a case with grade 3 VUR after balloon dilation is reported as a complication of URS [19]. Fortunately spontaneous resolution has been observed within one year. In another series including 19 URS with ureteral dilation, upper urinary tract dilation was observed in 5 cases [20]. Among these cases only one case had low-grade VUR on VCUG. In our study, ureteral dilatation was not required in any patient. The miniaturization of the instrumentation has enabled the ureteroscopy procedure to be performed with no need for ureteral orifice dilation.**

The use of a ureteral stent following ureteroscopy is reported in 13-100 % of the cases in pediatric ureteroscopy series [Table-2][10]. During the URS procedure, a DJ stent is placed generally because of ureteral injury, severe ureteral edema, and increased stone burden. In the pediatric micro-URS study on 2 cases published recently, no need for DJ stent placement was reported [9]. In our series, DJ stents were placed due to excessive edema in 3 cases.

Micro-URS has some limitations in addition to its technical advantages. Due to its short length, reaching the upper ureter may not be possible, especially in school-aged children and adolescents. Therefore, micro-URS seems to be a more appropriate instrument for especially distal ureteral stones. Still, its use is more convenient in girls because of the urethral configuration of boys. However, we performed micro-URS on 6 boys in our series.
As another limitation, it does not allow the insertion of a basket catheter or guide-wire though its working channel. **While the semi-rigid optics are more durable, the micro-optical system used during micro-URS is a fragile and costly instrument vulnerable to damage. The lack of the cost efficacy assessment may be considered as the limitation of the study.**

The limited number of patients and the lack of any comparative group may be regarded as the main limitations. However we believe that our study contributes the literature and presents the feasibility of this technique for the pediatric distal ureteral calculi.

CONCLUSION

The outcomes of our series show that micro-URS can be used safely and effectively in the treatment of pediatric distal ureteral stones. Further prospective and comparative studies comparing instruments of different size are warranted.

Table 1: Patient demographics and perioperative data and outcomes are summarized

Table 2: Outcome of ureteroscopy for ureterolithiasis in children

Figure 1: The micro-ureteroscope, 4.5Fr semirigid ureteroscope and 9.5Fr pediatric cystoscope are set ready on the operating table.

Figure 2: Intraoperative fluoroscopy and endoscopy images

REFERENCES

1. Sas DJ. An update on the changing epidemiology and metabolic risk factors in pediatric kidney stone disease. Clin J Am Soc Nephrol 2011;6:2062-8.
2. Tekgül S, Dogan HS, Hoebeke P, et al. Guidelines on Paediatric Urology. European Society for Paediatric Urology. European Association of Urology 2016.
3. Onal B, Citgez S, Tansu N, et al. What changed in the management of pediatric stones after the introduction of minimally invasive procedures? A single-center experience over 24 years. J Pediatr Urol 2013;9:910-4.
4. Tanriverdi O, Silay MS, Kendirci M, et al. Comparison of ureteroscopic procedures with rigid and semirigid ureteroscopes in pediatric population: does the caliber of instrument matter? Pediatr Surg Int 2010;26:733–8.
5. Atar M, Sancaktutar AA, Penbegul N, et al. Comparison of a 4.5 F semi-rigid ureteroscope with a 7.5 F rigid ureteroscope in the treatment of ureteral stones in preschool-age children. Urol Res 2012;40:733-8.
6. Kurzrock EA, Huvman JL, Hardy BE, et al. Endoscopic treatment of pediatric urolithiasis. J Pediatr Surg 1996;31:1413–6.
7. Desai M, Mishra S. 'MicroPerc' micro percutaneous nephrolithotomy: Evidence to practice. Curr Opin Urol 2012;22:134–8.
8. Caballero JP, Galán JA, Verges A, et al. Micro-ureteroscopy: Initial experience in the endoscopic treatment of pelvic ureteral lithiasis. Actas Urol Esp 2015;39:327-31.
9. Caballero-Romeu JP, Budia-Alba A, Galan-Llopis JA, et al. Microureteroscopy in Children: Two First Cases. Journal of Endourology Case Reports 2016;2:44–7.

10. Ishii H, Griffin S, Somani BK. Ureteroscopy for stone disease in the paediatric population: a systematic review. BJU Int 2015;115:867-73.

11. Raza A, Smith G, Moussa S, et al. Ureteroscopy in the management of pediatric urinary tract calculi. J Endourol 2005;19:151-8.

12. Ritchey M, Patterson DE, Kelalis PP, Segura JW. A case of pediatric ureteroscopic lasertripsy. J Urol. 1988; 139(6):1272-4.

13. Schuster TG, Hollenbeck BK, Faerber GJ et al. Complications of ureteroscopy: analysis of predictive factors. J Urol 2001;166:538–40.

14. Koura AC, Ravish IR, Amarkhed S, et al. Ureteroscopic stone management in prepubertal children. Pediatr Surg Int 2007;23:1123–6.

15. El-Assmy A, Hafez AT, Eraky I, et al. Safety and outcome of rigid ureteroscopy for management of ureteral calculi in children. J Endourol 2006;20:252–5.

16. Kocaoglu C, Ozkan KU. The effectiveness of 4.5F ultrathin semirigid ureteroscope in the management of ureteral stones in prepubertal children: is there a need for any ureteral dilatation? Urology 2014;84:202-5.

17. Bodakci MN, Sancaktutar AA, Dağgulli M, et al. Micropercutaneous cystolithotomy in children: our experience with the transillumination technique. J Endourol 2014;28:693-8.

18. Silay MS, Tepeler A, Sancaktutar AA, et al. The all-seeing needle instead of the Veress needle in pediatric urologic laparoscopy. J Endourol 2013;27:1376-80.

19. Thomas R, Ortenberg J, Lee BR, et al. Safety and efficacy of pediatric ureteroscopy for the management of calculous disease. J Urol 1993;149;1082-4.

20. Al Busaidy SS, Prem AR, Medhat M. Paediatric ureteroscopy for ureteric calculi: A 4–year experience. Br J Urol 1997;80:797–801.

21. Bassiri A, Ahmadnia H, Darabi MR, et al. Transureteral lithotripsy in pediatric practice. J Endourol 2002;16:257-60.

22. Schuster TG, Russell KY, Bloom DA, et al. Ureteroscopy for the treatment of urolithiasis in children. J Urol 2002;167:1813-5.

23. Thomas JC, DeMarco RT, Donohoe JM, et al. Pediatric ureteroscopic stone management. J Urol 2005;174:1072-4.

24. Minevich E, Defoor W, Reddy P, et al. Ureteroscopy is safe and effective in prepubertal children. J Urol 2005;174:276-9.

25. De Dominicis M, Matarazzo E, Capozza N, et al. Retrograde ureteroscopy for distal

ureteric stone removal in children. BJU Int 2005;95:1049-52.

26. Tan AH, Al-Omar M, Denstedt JD, et al. Ureteroscopy for pediatric urolithiasis: an evolving first-line therapy. Urology 2005;65:153-6.

27. Smaldone MC, Cannon GM Jr, Wu HY, et al. Is ureteroscopy first line treatment for pediatric stone disease? J Urol 2007;178:2128-31

28. Gedik A, Orgen S, Akay AF, et al. Semi-rigid ureterorenoscopy in children without ureteral dilatation. Int Urol Nephrol 2008;40:11-4.

29. Kim SS, Kolon TF, Canter D, et al. Pediatric flexible ureteroscopic lithotripsy: the children's hospital of Philadelphia experience. J Urol 2008;180:2616-9.

30. Turunc T, Kuzgunbay B, Gul U, et al. Factors affecting the success of ureteroscopy in management of ureteral stone diseases in children. J Endourol 2010;24:1273-7.

31. Nerli RB, Patil SM, Guntaka AK, et al. Flexible ureteroscopy for upper ureteral calculi in children. J Endourol 2011;25:579-82.

32. Dogan HS, Onal B, Satar N, et al. Factors affecting complication rates of ureteroscopic lithotripsy in children: results of multi-institutional retrospective analysis by Pediatric Stone Disease Study Group of Turkish Pediatric Urology Society. J Urol 2011;186:1035-40.

	Age (month)	Gender	Stone size (mm)	Stone location	Procedure time (minutes)	Outcome	Stent	Hospitalization (hours)	Complication
1	37	Girl	6	Distal	28	Stone free	None	22	None
2	31	Boy	9	Distal	38	Stone free	None	24	None
3	48	Boy	9	Distal	42	Stone free	None	20	None
4	23	Girl	11	Distal	46	Stone free	DJ Stent	24	None
5	70	Boy	24	Distal	68	Stone free	DJ Stent	24	Mild hematuria
6	68	Boy	8	Distal	36	Stone free	None	24	None
7	161	Girl	9	Distal	26	Stone free	None	18	None
8	6	Boy	6	Distal	23	Stone free	None	21	None
9	79	Boy	8	Distal	28	Stone free	None	20	None
10	38	Girl	12	Distal	30	Stone free	None	10	None
11	45	Boy	16	Distal	40	Stone free	DJ Stent	28	None
Mean	55.1		10.5		36.8			21.4	1/11

Table 1: Patient demographics and perioperative data and outcomes are summarized

	Year	No patients (procedures)	Mean age (years)	Mean stone size (mm)	Ureteroscope	Dilation/ Prestenting (%)	Postoperative stenting (%)	Stone free rate (%)	Complication rate (%)
Al Busaidy [20]	1997	50	5.2	12.6	8.5Fr, 9.5Fr and 11.5Fr	38	92	91.7	4
Bassiri [21]	2002	66	9	8	8F semirigid and 11.5Fr	37.9	Routine ureteral catheter	88	22.7
Schuster [22]	2002	25 (27)	9.2	2-12	6.9Fr flexible, 8Fr rigid	56	70	92	7.4
Raza [13]	2005	52	5.9	8.8	6.8Fr semirigid	3.8	21.15	91	19.2
Thomas [23]	2005	29 (33)	7.8 (0.4-12)	7-14	7.5Fr semirigid or flexible	27.6	93	88	3.0
Minevich [24]	2005	71 (81)	7.5	NA	6.9Fr semirigid or 7Fr flexible	30	85	98	1.2
De Dominicis [25]	2005	17 (17)	8.1 (2-17)	7.6(6-10)	7.5Fr semirigid	11.7	11.7	94	0
Tan [26]	2005	29 (33)	9.1 (1.5-14)	9	NA	17.4	91	95.2	3.4
El-Assmy [15]	2006	32 (32)	8.7 (2-15)	4-15	8Fr	28.5	97.1	90.7	15.7
Koura [14]	2007	20 (22)	5.2 (3-9)	6 (4-14)	6/7.5 semirigid and 8F flexible	100	30	90	13.6
Smaldone [27]	2007	100 (115)	13.2	8.3	7.5 semirigid and/or 6.9Fr flexible	66.6/49	78	91	5.1
Gedik [28]	2008	54	8.5 (1-16)	7.1 (4-12)	7.5Fr semirigid	None	Routine ureteral catheter	77.8	5.5
Kim [29]	2008	170	5.2	6.1 (3-24)	6.9 or 7.5Fr flexible	57	100	98.5	0
Tanriverdi	2010	65	9.05	9.5 (3-	6.9Fr or 8Fr	1.5	41.5	89.2	4.6

[4]			(2-16)	30)	semirigid				
Turunc [30]	2010	66	8.1 (0.5-16)	8.2 (4-20)	8Fr rigid	7.5	55	84.8	3.0
Nerli [31]	2011	88	5.2	10.2 (7-16)	6.9 or 7.5Fr flexible	31.25	NA	90	20.4
Dogan [32]	2011	660	7.5	8.9	4Fr to 10Fr semirigid	30.9	61.7	92.8	6.8
Atar [5]	2012	69	4.3	7.2	4.5Fr or 7.5Fr semirigid	10.1	71.0	85.6	52.2
Kocaoglu [16]	2014	36 (38)	5.3 (1-13)	8.38 (4-18)	4.5-6Fr	0	42.1	97.4	0

NA: Not available

Table 2: Outcome of ureteroscopy for ureterolithiasis in children

Figure 1

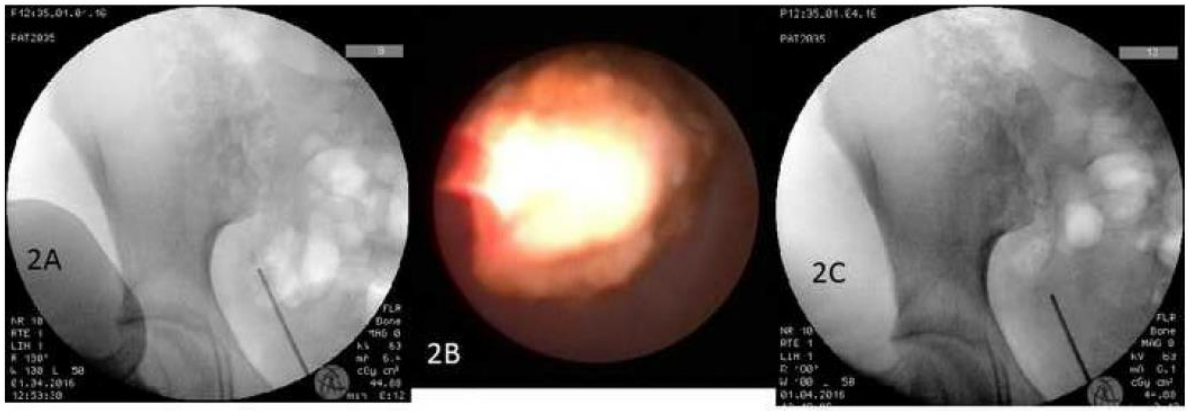

Figure 2